

CASE REPORT

The role of multimodality radiological imaging in extrauterine misplaced IUCD: A case report

DOI: 10.29063/ajrh2020/v24i4.21

Augustina Badu-Peprah^{1,2*}, Theophilus K. Adu-Bredu³, Charles Adu-Takyi³

Radiology Directorate - Komfo Anokye Teaching Hospital¹; Radiology Department - Kwame Nkrumah University of Science and Technology, School of Medicine and Dentistry²; Obstetrics and Gynaecology Directorate, Komfo Anokye Teaching Hospital³

*For Correspondence: Email: augustinabadupeprah@gmail.com

Abstract

Intrauterine contraceptive device (IUCD) is among the commonly used contraceptive methods in the world including sub-Saharan Africa but have been associated with a number of complications that although rare, can occur. Uterine perforation is the most serious complication of the IUCD. Surgical management is required in cases with complete uterine perforation, in which the IUCD is partially or completely within the peritoneal cavity. We present a case of a 27-year-old para 2 woman reporting with mild lower abdominal pains and the absence of IUCD string in the vagina after its insertion following evacuation of the uterus 2 years prior to this study. With the utilization of multiple imaging modalities, an exploratory laparotomy was done to remove the migrated IUCD and repair of the perforated bowel and urinary bladder. (*Afr J Reprod Health* 2020; 24[4]: 213-217).

Keywords: Migrated IUCD, uterine perforation, ultrasonography, radiography, Computed Tomography

Résumé

Le dispositif contraceptif intra-utérin (IUCD) fait partie des méthodes contraceptives couramment utilisées dans le monde, y compris en Afrique subsaharienne, mais a été associé à un certain nombre de complications qui, bien que rares, peuvent survenir. La perforation utérine est la complication la plus grave de l'IUCD. Une prise en charge chirurgicale est nécessaire dans les cas de perforation utérine complète, dans laquelle l'IUCD est partiellement ou complètement dans la cavité péritonéale. Nous présentons le cas d'une femme Para 2 de 27 ans qui a rapporté avec des légères douleurs abdominales basses et l'absence de fil du dispositif contraceptif intra-utérin dans le vagin après son insertion suite à l'évacuation de l'utérus 2 ans avant cette étude. L'utilisation des multiples modalités d'imagerie, une laparotomie exploratoire a été réalisée pour retirer l'IUCD migré et réparer l'intestin et la vessie perforés. (*Afr J Reprod Health* 2020; 24[4]: 213-217).

Mots-clés: IUCD migré, perforation utérine, échographie, radiographie, Tomodensitométrie

Introduction

Intrauterine contraceptive device (IUCD) is among the commonly used contraceptive methods in the world including sub-Saharan Africa¹. It is associated with several complications even though rare. These complications include infection, uterine bleeding, ectopic pregnancy, and uterine perforation². Perforation by IUCD can involve several neighboring organs such as the urinary bladder and rectosigmoid³. Uterine perforation is the most serious complication of the IUCD, occurring in 1.6 per 1000 insertions⁴. Surgical management is required in cases with complete uterine perforation, in which the IUCD is partially

or completely within the peritoneal cavity^{3,5}. The radiologist plays an important role in the diagnosis of IUCD migration using multiple imaging modalities, for careful assessment of intraabdominal complications, since emergency intervention maybe warranted⁵. Due to the increased risk of complications that could arrive from sporadic exploratory surgeries, adequate planning before surgeries is essential to reduce duration of surgery as well as surgical complications. We therefore present a case of how a combination of multiple radiological imaging modalities aided in accurate mapping of the location of IUCD and associated regional perforation.

Case Presentation

A 27-year-old Para 2 woman reported with mild lower abdominal pains and the absence of IUCD string in the vagina after its insertion 2 years ago following evacuation of the uterus.

An initial pelvic x-ray showed the presence of the IUCD in the pelvis but deviated to the right (Figure 1). A pelvic ultrasound was subsequently performed using both transabdominal and transvaginal approach. This revealed an empty uterus and a linear echogenic structure in the right adnexa, lateral to the urinary bladder with surrounding bowel loops (figures 2.0 and 3.0) which was believed to be the IUCD. A complimentary computed tomography (CT) revealed simultaneous bowel and urinary bladder wall perforation by the migrated IUCD with no pelvic abscess (Figure 4.0).

An exploratory laparotomy performed revealed a 3mm perforation of the ileum in the anti-mesenteric border about 17cm from the ileocecal junction. The horizontal arm of the IUCD was completely buried within the bowel lumen while the vertical arm was buried within the serosa of the urinary bladder with the string buried within the serosa of the bowel. A 1mm size dimple was found at the anterior wall of the uterus about 3cm from the fundus. The fallopian tubes and ovaries appeared normal. The IUCD was removed and the bowel and serosa of the urinary bladder were repaired.

Discussion

Uterine perforation is a known complication after insertion of IUCD. Insertion of the device post abortion, postpartum during lactation as well as retroverted uterus are risk factors for uterine perforation^{6,7}. In our case, the IUCD was inserted after evacuation of uterus which increased the risk of uterine perforation. Perforation usually occurs at the time of insertion but the IUCD may be embedded in the uterus. Subsequent uterine contractions forces the embedded IUCD through the wall into the pelvic or abdominal cavity or into adjacent organs such as the rectosigmoid, urinary bladder, and even appendix⁸⁻¹⁰. In our case, the migrated IUCD simultaneously perforated the ileum and serosa of the urinary bladder. Cervical

perforations have also been identified where the IUCD remains in situ and the IUCD strings penetrate the anterior vaginal wall and urinary bladder¹¹.

Most perforations though occur at the time of insertion, it may not be recognized until years later because they are usually asymptomatic as in our case. Although, it has been suggested that surgical removal may not be necessary in asymptomatic patients¹², severe morbidity such as bowel obstruction, abscess and fistula may occur with intraabdominal device². The triad of abdominal pain, fever and intermittent diarrhea associated with a missing IUCD has been suggested as representing the signs and symptoms of bowel injury¹¹. In this present case, the patient only presented with mild lower abdominal pain despite simultaneous perforation of urinary bladder and ileum. No sign of peritonitis was evident clinically and at surgery. This could be explained as due to the small diameter of perforation (1mm). Also, since urinary bladder perforation was limited to the serosa without intraluminal extension, severe symptoms of urinary bladder injury were unlikely.

If a patient becomes pregnant or the IUCD string is not visible at the external os, uterine perforation should be suspected; as in this present study where the IUCD string was not visible at the external os in a non-pregnant woman. Uterine perforation post abortion in our case was evident by the 1mm dimple seen at the anterior wall of the uterus at surgery.

Vaginal ultrasonography, pelvic radiography, hystero-graphy and pelvic Computed Tomography (CT) are radiological imaging that can be used to accurately determine the location and possible complications of a misplaced IUCD. If the IUCD is not located within the endometrial cavity, plain radiography, hystero-graphy and CT of the abdomen and pelvis can be useful for diagnosis^{2,13,14}. In the present study, a combination of plain radiography, sonography and CT of the pelvis helped in carefully mapping the location of the misplaced IUCD and surrounding visceral perforations. This enabled proper and adequate planning for the surgical procedure.

The normal removal of intrauterine contraceptive devices within the uterus is by pulling it out by its

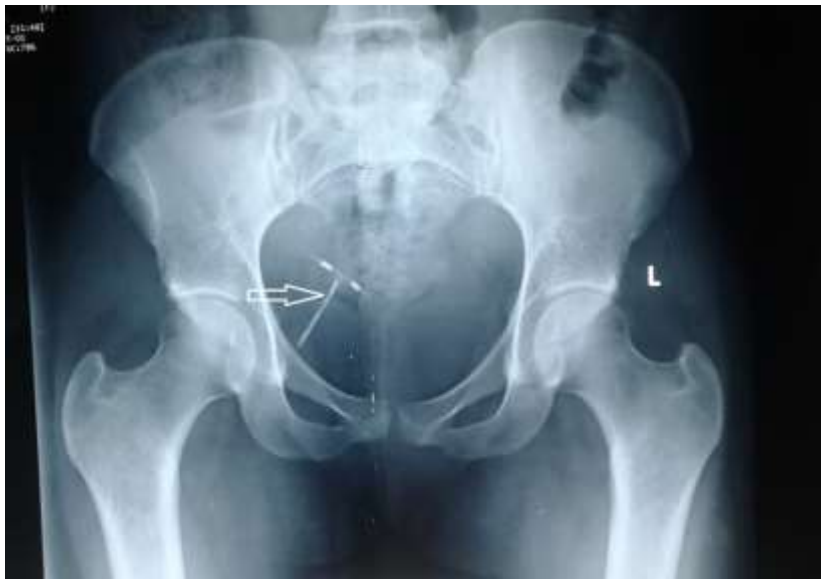

Figure 1: Showing right deviation of IUCD (white arrow) in the pelvis on x –ray

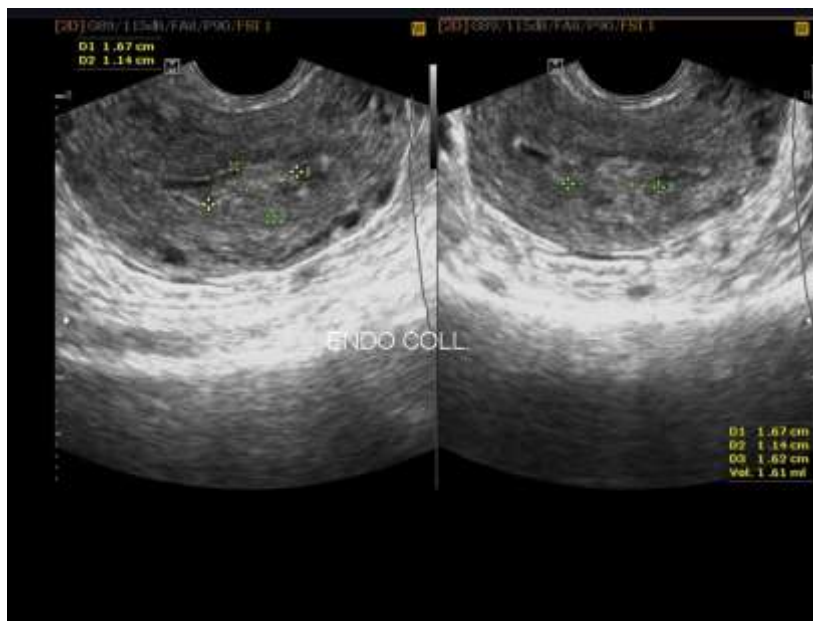


Figure 2.0: Ultrasound shows minimal endometrial collection but with absent IUCD in the cavity

strings, and if the strings are missing, IUCD within the uterus may be removed by dilation and curettage or hysteroscopy. In cases where the IUCD has migrated outside the endometrial cavity or intra-abdominally, recommended methods of removal of the IUCD from the perforated viscous, include cystoscopy, colonoscopy, laparoscopy and appendectomy¹⁵⁻¹⁸. Currently the accepted treatment for removal of a misplaced IUCD is

surgical removal through laparoscopy or laparotomy¹⁶.

In our case report with missing IUCD thread in vagina, the combination of multiple imaging modalities using pelvic radiography, ultrasound, and CT, made it possible for accurate mapping of the location of the migrated IUCD. The revelation of simultaneous perforation of the urinary bladder and the small bowel by the IUCD

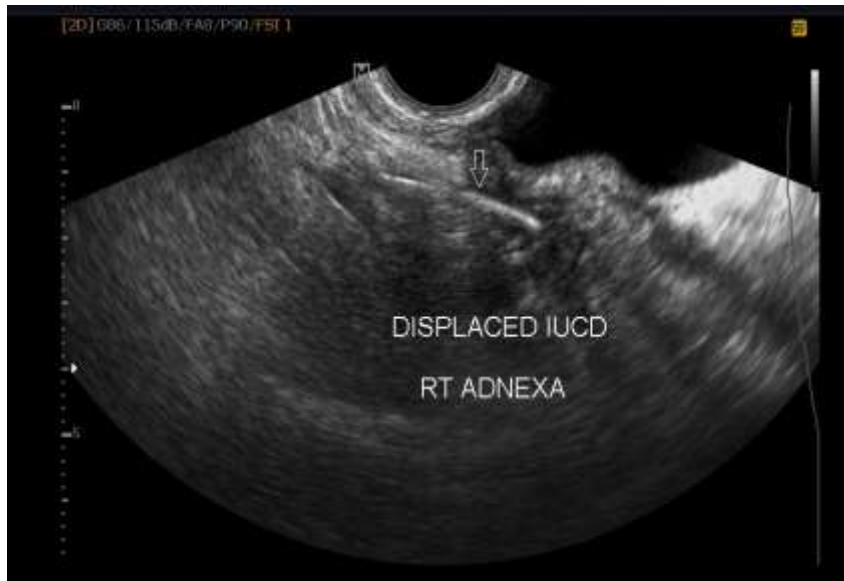

Figure 3.0: Transvaginal image showing an echogenic linear structure at the right adnexa suspected to be IUCD (White arrow)

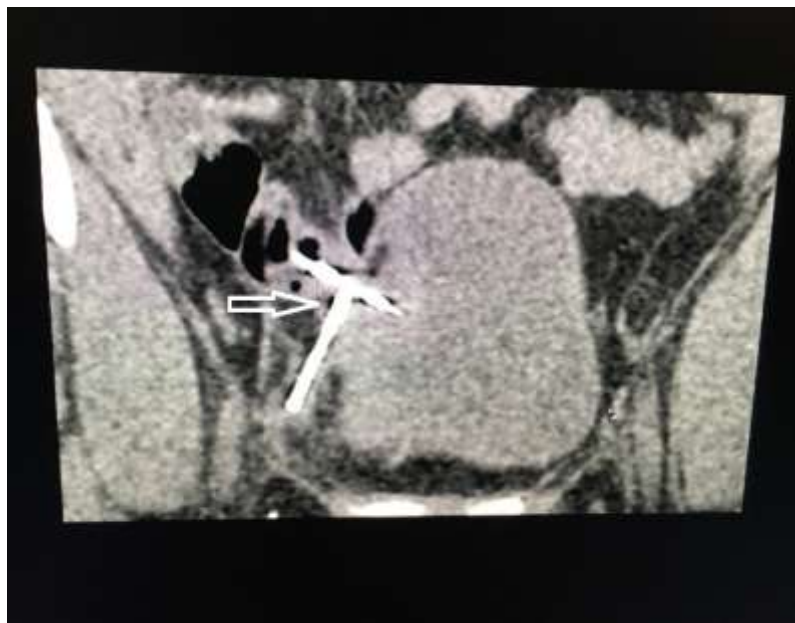

Figure 4.0: Showing CT image of simultaneous perforation of small bowel and right lateral urinary bladder wall (white arrow)

on imaging influenced the decision to perform laparotomy to remove the misplaced IUCD.

Contribution of Authors

Augustina Badu-Peprah: Principal Investigator: Was responsible for the following:

- Filing for ethical approval
 - Reported the pelvic X-ray and computed tomography of the patient
 - Part of the write up, finalization and submission of manuscript.
 - Final approval of the version to be published
- Theophilus Adu-Bredu: Was responsible for;

- Performed the ultrasound of the patient
- Part of the write up, finalization and submission of manuscript.

Final approval of the version to be published

Charles Adu-Takyi: Was responsible for;

- Performed the surgery for the patient
- Part of the write up, finalization and submission of manuscript.

Final approval of the version to be published.

References

1. Tsui AO, Brown W and Li Q. Contraceptive Practice in Sub-Saharan Africa. *Popul Dev Rev.* 2017 May;43(Suppl Suppl 1):166–91.
2. Mederos R, Humaran L and Minervini D. Surgical removal of an intrauterine device perforating the sigmoid colon: A case report. *Int J Surg.* 2008 Dec 1;6(6):e60–2.
3. Ohana E, Sheiner E, Leron E and Mazor M. Appendix perforation by an intrauterine contraceptive device. *Eur J Obstet Gynecol Reprod Biol.* 2000 Feb 1;88(2):129–31.
4. Harrison-Woolrych M, Ashton J and Coulter D. Uterine perforation on intrauterine device insertion: is the incidence higher than previously reported? *Contraception.* 2003 Jan 1;67(1):53–6.
5. Boortz HE, Margolis DJA, Ragavendra N, Patel MK and Kadell BM. Migration of intrauterine devices: radiologic findings and implications for patient care. *Radiogr Rev Publ Radiol Soc N Am Inc.* 2012 Apr;32(2):335–52.
6. Andersson K, Ryde-Blomqvist E, Lindell K, Odland V and Milsom I. Perforations with intrauterine devices: Report from a Swedish survey. *Contraception.* 1998 Apr 1;57(4):251–5.
7. Rowlands S, Oloto E and Horwell DH. Intrauterine devices and risk of uterine perforation: current perspectives. *Open Access J Contracept.* 2016 Mar 16;7:19–32.
1. Carson SA, Gatlin A and Mazur M. Appendiceal perforation by Copper-7 intrauterine contraceptive device. *Am J Obstet Gynecol.* 1981 Jan 1;141(6):586–7.
2. Madden A, Aslam A and Nusrat NB. A Case of Migrating “Saf-T-Coil” Presenting with a Vesicovaginal Fistula and Vesicovaginal Calculus. *Urol Case Rep.* 2016 Jul 1;7:17–9.
3. Gyasi-Sarpong CK, Maison POM, Morhe E, Aboah K, Appiah KA-A, Azorliade R, Baah-Nyamekye K, Otu-Boateng K, Amoah G, Antwi I, Frimpong-Twumasi A and Arthur D. Intravesical migration of an intrauterine device. *BMC Res Notes.* 2016 Jan 2;9(1):4.
4. Savardekar LS, Shah RS and Vandana W. Asymptomatic cervical perforation by intrauterine copper bearing contraceptive device: two unusual cases. *Eur J Obstet Gynecol Reprod Biol.* 2005 Jun 1;120(2):236–7.
12. Markovitch O, Klein Z, Gidoni Y, Holzinger M and Beyth Y. Extrauterine mislocated IUD: is surgical removal mandatory? *Contraception.* 2002 Aug 1;66(2):105–8.
5. Family Planning Worldwide – 2008 Data Sheet [Internet]. HEART. [cited 2020 Apr 6]. Available from: https://www.heart-resources.org/doc_lib/family-planning-worldwide-2008-data-sheet/
6. Diouf A, Moussa D, Gassama O, Niang M, Thiam M, Gueye M, Mbaye M, Moreau JM, Van Herendael B and Diouf A. Migration of intrauterine device into the pelvic cavity: exploration strategy and management in African environment. *Int J Reprod Contracept Obstet Gynecol.* 2017 Jan 31;6:757.
15. Chi E, Rosenfeld D and Sokol TP. Laparoscopic Removal of an Intrauterine Device Perforating the Sigmoid Colon: A Case Report and Review of the Literature [Internet]. 2005 [cited 2020 Apr 6]. Available from: <https://www.ingentaconnect.com/content/sesc/tas/2005/00000071/00000012/art00014>
16. Medina TM, Hill DA, DeJesus S and Hoover F. IUD removal with colonoscopy: a case report. *J Reprod Med.* 2005 Jul;50(7):547–9.
17. Vahdat M, Gorginzadeh M, Mousavi AS, Afshari E and Ghaed MA. Cystoscopic removal of a migrated intrauterine device to the bladder; a case report. *Contracept Reprod Med.* 2019 Jul 1;4(1):7.
18. Stuckey A, Dutreil P, Aspuru E and Nolan TE. Symptomatic cecal perforation by an intrauterine device with appendectomy removal. *Obstet Gynecol.* 2005 May;105(5 Pt 2):1239–41.